

One24 Burn Soother

Great for Reducing Pain,

Discomfort and Scarring

Warning burn victim pictures may be disturbing to some people.

The below pictures have been included with the consent of the burn victim's parents who contacted Graeme to see if his burn soother would help to alleviate their son's pain and reduce any potential scarring.

The sequence of treatment and photographs takes place over a period of 14 days, commencing 7th November finishing on the 20th November when the patient was discharged from hospital.

Graeme was allowed to begin his burn treatment on the third day after the accident.

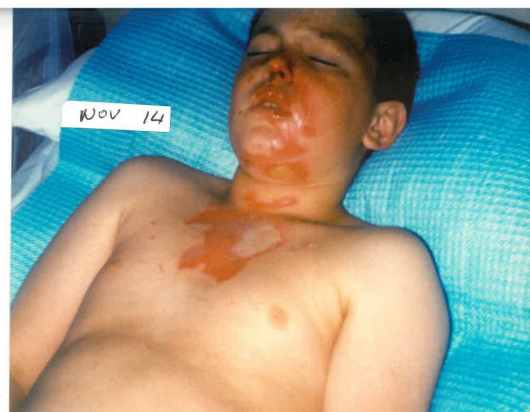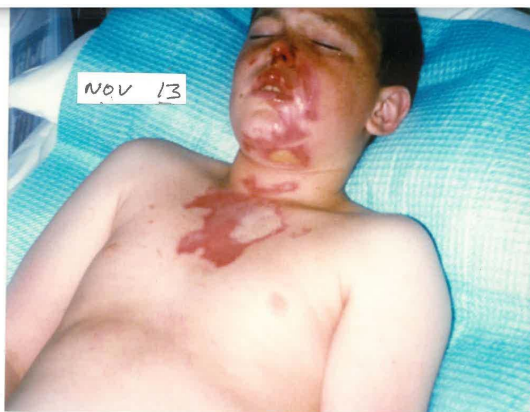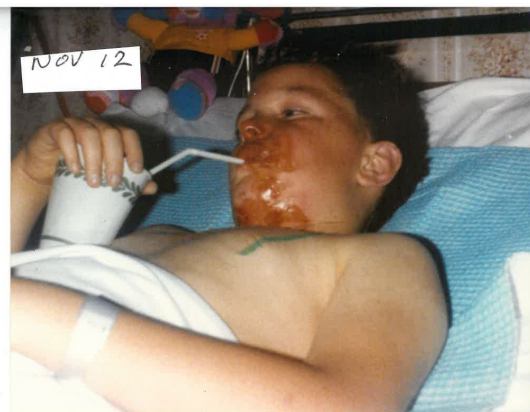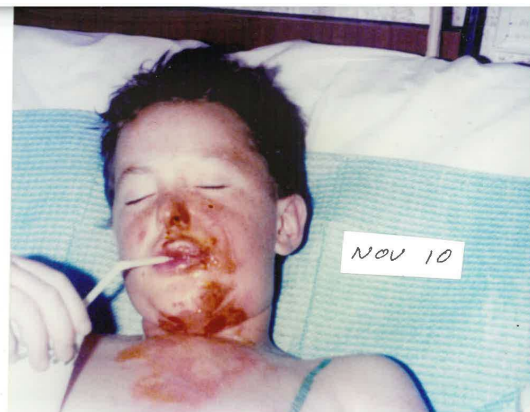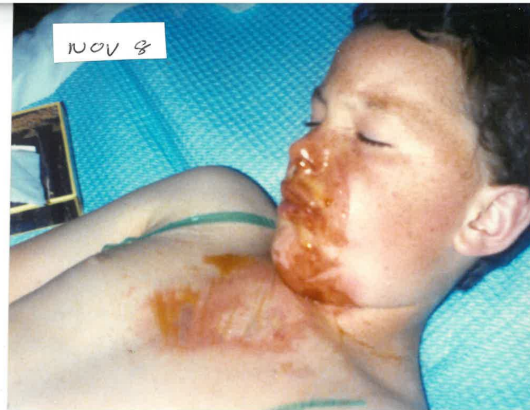
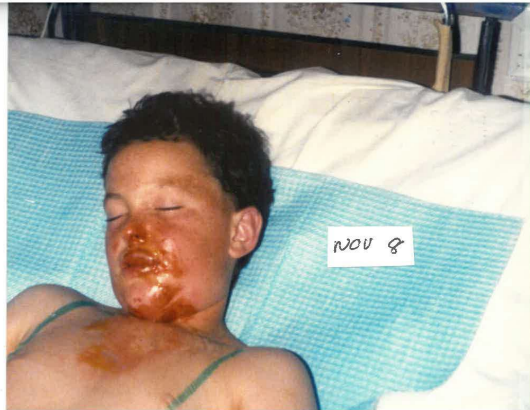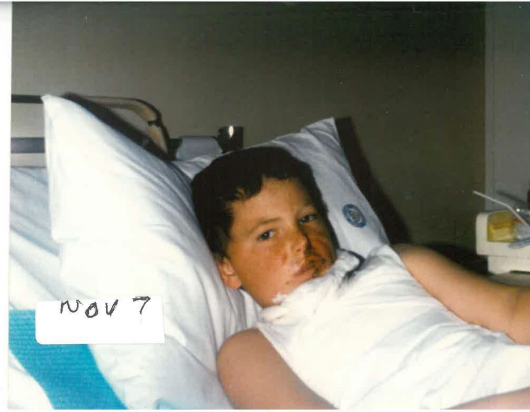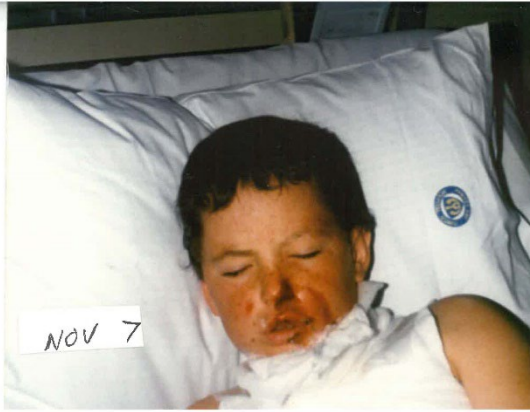As can be seen from pictures 1 and 2 dated Nov 7 the patient's burn sites had been disinfected and covered in the usual manner to help prevent further infection, and to let nature take its course to shed the burnt and damaged skin tissues prior to any skin grafts.

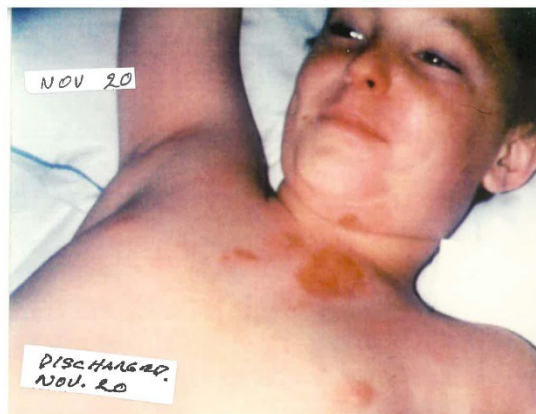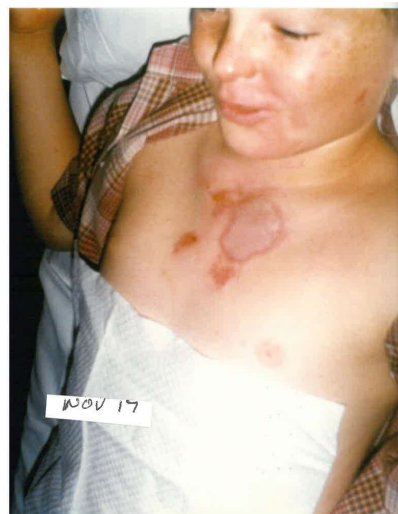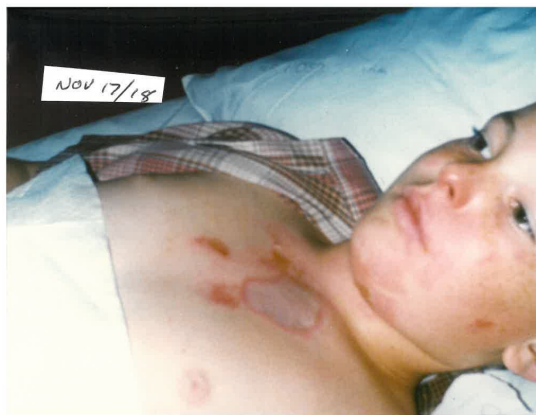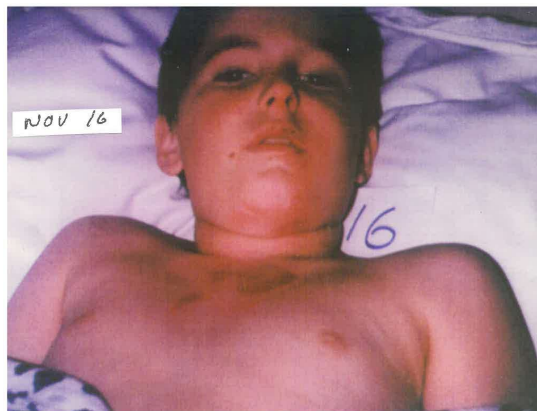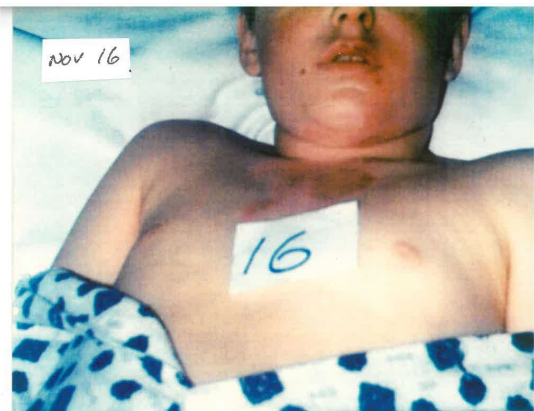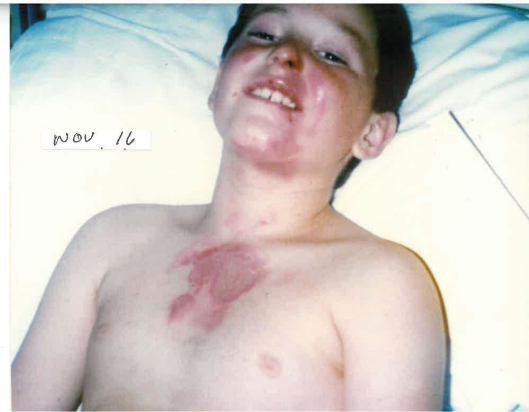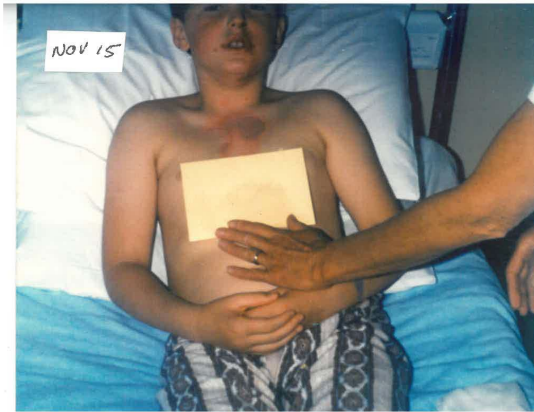Graeme uncovered and exposed the burn sites and applied a thinned down version of our Burn Soother with a soft brush so as to avoid further pain from touching the burn site with his hands. Relief from the searing, burning sensation was felt almost immediately and the patient who had not been able to sleep since the accident, owing to the intense pain, was able to finally sleep and went into a deep sleep for nearly two days as can be seen from the next two photos dated Nov 8.

Graeme applied our Burn Soother three times per day for the first two days, then twice per day for the next seven days, and once per day until his discharge on the 20th November. No other treatments including antibiotics were administered.

This patient, as can be seen from the earlier pictures, was a definite candidate for skin grafts to the burn areas on his chest and under his chin. However, thanks to our burn soother and as can be seen from the last pictures, no skin grafts were required. Additionally, no contractus conditions or other complications occurred.

As can be seen from the pictures the healing process was very rapid which resulted in minimal scarring. The final scarring on his chest was approximately the size of a 10-cent piece, the scar under his chin about a quarter of the size of the scar on his chest and no scarring at all to his lips, nose and rest of his face.





Our Burn Soother, as can be seen from the photographs, has proven to be exceptionally good in healing even the largest of burns. An additional benefit to the healing process, is the comfort provided to the patient from pain relief provided by our Burn Soother.